



Community Paediatric Review

A NATIONAL PUBLICATION FOR COMMUNITY CHILD HEALTH NURSES AND OTHER PROFESSIONALS

VOL 8 NO 1 MARCH 1999

An initiative of the
Centre for Community
Child Health,
Royal Children's
Hospital, Melbourne

Visual development in childhood

Vision impacts on virtually every moment of our waking lives. Abnormal vision may interfere with many aspects of a child's development and interaction with their environment. Visual cues are used by very young infants and parents alike. If a blind baby is picked up without auditory warning she/he may well startle and stiffen; while a sighted child, having seen the approaching parent, may react in an animated and excited manner. These differences will affect the parent's interaction with the child.

EXECUTIVE INDEX

Visual development in childhood 1

Common eye problems 2

In common with the other special senses, visual experience is difficult to describe and even harder to define. The basic apparatus that enables us to see is more easily described. The eyes are like video cameras. There is a focusing mechanism (the cornea and lens) and a converting film which transforms a focused picture into an electrical signal (the retina and optic nerve). The analogy with a video breaks down here as humans do not store visual information on a blank tape to look at later.

The visual information "collected" by the eyes is analysed in detail for shape, colour and motion and compared to remembered visual experience and with other experience such as language to give meaning to vision. This analysis occurs initially in the visual cortex (occipital lobe) and the related areas of the brain. A useful analogy for descriptive purposes is to consider the brain processing of vision as rather like a computer analysing information.

An understanding of normal visual behaviour is vital to estimating visual function in infancy. An infant at birth, when alert, should be able to fix on a face briefly. By six weeks of age most infants smile in a visually responsive fashion to a face. At this age the infant will also be able to follow a face or light through an arc of 90°. By six months of age an infant can reach for a small object and actively follow objects in the visual environment. At twelve months of age a child should be able to

reach and pick up tiny objects such as hundreds-and-thousands ('sprinkles').

More formal assessment of visual acuity becomes possible with the development of language. Children with specific language delay or more general intellectual delay will have difficulty with these tests of visual acuity. Picture naming tests (e.g. Kay Picture Test) can be done by children between two and three years of age. Single letter matching tests are within the abilities of most three to four year olds. The standard Snellen chart test is often not performed well until the child is between five and six years of age. The vision should be tested for each eye individually. As with all testing in children, patience and an encouraging manner are vital to obtain the best results. Repeat the test on another occasion if the test results seem inaccurate.

A screening test specific for preschool children has been developed by the School of Orthoptics at Latrobe University. The Melbourne Initial Screening Test (MIST) is currently being used by Maternal and Child Health Nurses in Victoria. Children who fail the test have visual acuity of less than 6/10.

The notation for documenting visual acuity is the Snellen fraction; e.g. 6/6. Most visual acuity tests use standard distances of three or six metres between subject and chart. When testing vision always ensure that the distance between the test chart and the child is correct and that the area is well illuminated (standard fluorescent lights are generally quite adequate).

SUPPORTED BY AN EDUCATIONAL GRANT FROM

WYETH

HEALTH AND NUTRITION TEL 1800 55 2229



CENTRE FOR COMMUNITY CHILD HEALTH, ROYAL CHILDREN'S HOSPITAL, MELBOURNE



The decision to refer a child for further assessment depends in part on the age of the child. An infant who is not fixing and following by three to four months, or reaching for small objects and tracking objects in the visual environment by eight to twelve months, deserves further examination and investigation. It is wise to always take note of the parents' views on their child's vision. If the parents are concerned, you should be too.

If the child is able to perform a more formal test of acuity, a difference between the two eyes of two or more lines (i.e. 6/6 and 6/12) indicates a need for further assessment. In children less than three years of age, vision of 6/18 or less in either eye should prompt referral, and in children older than three years 6/12 is an acceptable cut off for referral.

Reduced vision may be the result of abnormalities in the eye, the visual pathways from eye to brain or the brain itself. A refractive error is a defect in the focusing capabilities of the eye and in such cases the vision will generally improve with the prescription of glasses. A squint (turned eye) may result in reduced vision if one eye is favoured over the other. This favouring of one eye is amblyopia and is reversible if the problem is detected before six to seven years of age and appropriate treatment instituted; (Early diagnosis of amblyopia increases the possibility of a successful treatment outcome).

A squint may be obvious on observation alone or may be detected by the cover test. The cover test is performed by first getting the child to fix on an object

while the observer determines which eye appears to be misaligned. The eye that appears to be fixing on the object (and not misaligned) is then covered while the apparently misaligned eye is observed. If a squint is present a corrective movement of the misaligned eye will be seen as this eye takes up fixation on the object of regard. If no movement is seen then the eye is uncovered. The cover test is then repeated but the other eye is covered this time and the eye which is not covered is again observed for a corrective movement and if present a squint is confirmed. If no movement is seen following repeated covering of either eye then no squint is present. Any child over six months of age with a definite squint should be referred for further assessment.

Prematurity, perinatal difficulties (e.g. birth asphyxia), significant syndromes (e.g. Down syndrome) and other sensory impairment (e.g. deafness) are associated with increased risk of eye disease. Developmental delay often interferes with assessment of visual acuity, especially if language or intellect is affected. Common childhood eye problems such as strabismus and refractive errors have a clearly identified familial tendency though the precise genetics is not well understood.

AUTHOR
DR JAMES ELDER
DIRECTOR, DEPARTMENT OF OPHTHALMOLOGY
ROYAL CHILDREN'S HOSPITAL, MELBOURNE

Common eye problems

Children's eyes are susceptible to many of the same diseases as adults, as well as some peculiarities of their own. Children are often more difficult to examine and serious diseases need to be excluded as children tend not to complain about visual disturbances which can suggest occult disease.

This article reviews some of the more common diseases and also suggests which symptoms and signs herald more complicated pathology.

The watery eye in a baby One of the most common problems within the first year of life is a blocked tear duct, which may be unilateral or bilateral [see Photograph 1]. The problem usually presents in the first few months of life as a clear discharge of tears. The eye itself is normal – it is not red or inflamed. However the

lower eyelid skin may be reddened from excoriation of copious tears. The blockage is usually in the nasolacrimal duct. Most of these improve without surgery by one year of age. In the meantime parents are encouraged to keep the lids clean and to remove any crusting with wet cotton wool or a clean face-washer.

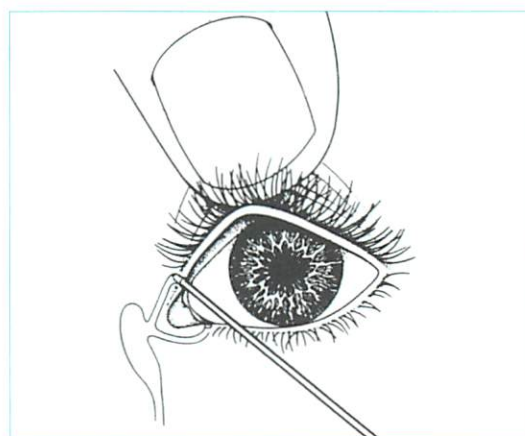
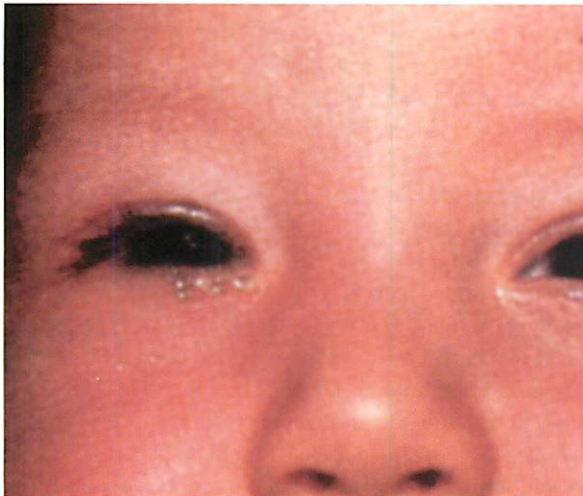

Figure 1: Introduction of probe tip through lacrimal punctum.



Photograph 1: Epiphora secondary to nasolacrimal duct obstruction

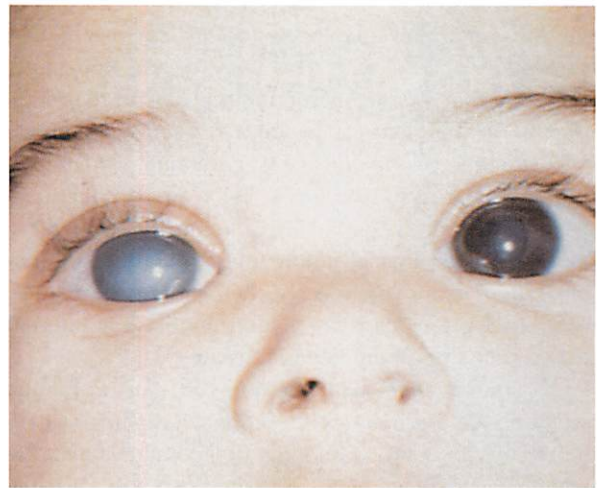Lacrimal massage is thought to help clear the tear sac of stagnant tear fluid so there is less bacterial build-up. Parents are instructed to massage on the side of the nose up to the inner angle of the eye and by doing so mechanically push debris and fluid out retrogradely through the puncta on the lids.

If there is no improvement or if there are frequent episodes of pussy discharge, then the treatment is to probe the lacrimal drainage system under general anaesthetic. A punctal dilator is inserted and then a probe is pushed down the canaliculus, through the lacrimal sac and into the nasolacrimal duct [see Figure 1]. A 'popping' feeling is often felt as the probe passes through the obstruction.

The key to the diagnosis is that in a blocked tear duct the eye itself is normal. It is not red and inflamed and the cornea is crystal clear. An enlarged eye with a cloudy cornea that is watering suggests a diagnosis of glaucoma [see Photograph 2]. This may be congenital glaucoma or a form of secondary glaucoma and will need to be managed immediately by an ophthalmologist.

Conjunctivitis Conjunctivitis may be viral, bacterial or allergic in nature. A frequent cause of allergic conjunctivitis is incorrect use of antibiotic drops for presumed bacterial conjunctivitis.

Viral conjunctivitis may begin unilaterally and progress to being bilateral. It is often associated with an upper respiratory tract infection. The conjunctiva is inflamed and there is usually some crusting of the lid margins. The discharge is watery and is a serous exudate combined with tears secreted as a result of the inflammation. Treatment is usually symptomatic. It is important to tell parents about lid hygiene and for crusts to be cleaned away. A child with prolonged or severe symptoms should be referred to an ophthalmologist. Viral conjunctivitis is highly contagious, particularly those caused by adenoviruses.



Photograph 2: Congenital glaucoma, right eye.

Bacterial conjunctivitis presents with a mucopurulent discharge. As with viral conjunctivitis, it can initially be unilateral but tends to progress to being bilateral. The conjunctivae are inflamed and erythematous. The eyelid margins are often adherent on rising in the morning. Again, lid hygiene is important as this helps to decrease the bacterial load. Without treatment, most mild bacterial conjunctivitis resolve after 10-14 days. Antibiotic treatment is usually to cover the common causes which are *Staphylococcus epidermidis*, *Staphylococcus aureus*, *Haemophilus* and *Streptococcus* species. Frequently used antibiotics are chloramphenicol and neomycin. A child with worsening symptoms or prolonged disease needs to be seen by an ophthalmologist. A mucopurulent conjunctivitis lasting for more than three weeks needs to have chlamydia infection excluded.

Allergic conjunctivitis is very common and often initially misdiagnosed as being infective. Hay fever (seasonal allergic conjunctivitis) has salient symptoms of itch, redness and lacrimation. These occur in the hay fever season and it is hypersensitivity to allergens (usually pollens) that are airborne.

Treatment depends on the severity of symptoms. Artificial tears make the eye more comfortable and help to dilute antigens in the tear fluid. Topical anti-histamines and decongestants/vasoconstrictors are beneficial and help reduce the itch and redness. Sodium cromoglycate (topically) and some topical nonsteroidal preparations are useful in more severe cases. Topical steroids are to be avoided unless the symptoms are not helped by other treatments.

Squint and pseudo strabismus The terms squint or strabismus refers to a turned eye. All cases of strabismus should be seen by an ophthalmologist as soon as possible. Strabismus is often associated with poor binocular vision and poor visual development. It can be

the cause of amblyopia: the so-called "lazy" eye. There are many reasons why this may occur. Congenital esotropia refers to a condition that begins in the first 6 months of life. There may be a refractive difference between the eyes (ie one eye is more long-sighted than the other and so the eyes can't focus together). Sometimes there is pathology in the eye itself or there may be a neurological problem. All squinting children need their vision documented. Refraction, external eye examination including full ocular motility, and internal eye examination should be performed.

Treatment then depends on the cause. Pseudo strabismus is a term used to describe the condition where there appears to be a squint but in fact there is not. The infant's facial appearance gives the impression that the eyes are crossed. The folds of the eyelid skin and the underdeveloped bridge of the nose give the appearance that the eyes are crossed. Many children present with a suspected squint and are in fact found to have pseudo strabismus. As there are serious conditions that can cause a squint it is important to exclude a true squint.

Foreign bodies These can occur as either a superficial problem or as an intraocular and thus more complicated situation.

Superficial foreign bodies can be on the cornea, conjunctiva or on the tarsal (underside) surface of the eye lids, where they are not visible but abrade the eye every time the lids blink. The child may present with a red eye and an obvious dark spot on the cornea. Alternatively, the eye may be red but no foreign body is seen until the lids are everted. Not all children can report the sensation of a foreign body or even give a history of it. Often foreign bodies are very small and can only be clearly seen under the illuminated magnification of a slit lamp. Foreign bodies on the cornea are generally removed with local drop anaesthesia and a cotton bud or 25 gauge needle. If the child will not remain still, general anaesthesia is required. Antibiotic ointment is then applied to the eye until the epithelium heals (24-48 hours). Complicated foreign bodies are those that actually perforate or

penetrate the eye. These need intraocular surgery for removal. Surgery is urgent. It is important therefore that penetrating foreign bodies are not removed by carers or children, but referred immediately.

Infection of lids Styes are infections of the hair follicles and their associated glands of the eye-lids. They are common in those with blepharitis. The infection is usually Staphylococcal and hence warm compresses and oral antibiotics are usually required.

Chalazia are lipogranulomatous inflammations of the Meibomian glands. They are thus not bacterial infections and do not require antibiotics. Warm compresses are the best treatment and if there is no resolution after one month then surgery (extirpation) can be considered. Children need a general anaesthetic but adults can cope with local anaesthesia. There are approximately 50 glands on each side so more can occur despite curettage of one.

Cellulitis Pre-septal cellulitis refers to an infection of the skin of the eye lids. The lid (or lids) are erythematous and indurated. The infection is usually staphylococcal. The introduction to Hib vaccine has made Haemophilus less likely in children younger than six years of age. Many affected children need admission to hospital for intravenous antibiotics. The most important step is to exclude orbital cellulitis. Orbital cellulitis involves the structures in the orbit. It usually begins from a sinus infection and spreads through the wall of the sinus into the orbit. An abscess may occur. This is an emergency and a CT scan is required. If an abscess is present then urgent surgery is needed to drain it. The abscess may involve more posterior structures such as the cavernous sinus and brain.

AUTHORS

DR. SUSAN CARDEN & DR. DEB COLVILLE

DEPARTMENT OF OPHTHALMOLOGY

ROYAL CHILDREN'S HOSPITAL

MELBOURNE.

 **Community Pædiatric Review**



SUPPORTED BY AN EDUCATIONAL GRANT FROM
WYETH HEALTH AND NUTRITION
TEL 1800 55 2229



CENTRE FOR COMMUNITY
CHILD HEALTH
ROYAL CHILDREN'S
HOSPITAL, MELBOURNE

Editors

Professor Frank Oberklaid

Michele Meehan

Jane Redden-Hoare

Chris Berry

Carolyn Briggs

Jenny Donovan

Marie Sheperd

Production Editor

Lyn Dredge

For further information contact the Centre for Community Child Health, Royal Children's Hospital, Melbourne. Phone 03 9345 5899 or Fax 03 9345 5900

© COPYRIGHT 1999. THIS PUBLICATION IS COPYRIGHT. APART FROM ANY FAIR DEALING FOR THE PURPOSE OF PRIVATE STUDY, RESEARCH, CRITICISM OR REVIEW AS PERMITTED UNDER THE COPYRIGHT ACT, NO PART MAY BE REPRODUCED BY ANY PROCESS OR PLACED IN COMPUTER MEMORY WITHOUT WRITTEN PERMISSION. ENQUIRIES SHOULD BE MADE TO THE PRODUCTION EDITOR.